



Histopathological Changes in the Muscle Tissue of the Fish *Clarias batrachus* Exposed to Untreated and Treated Sago Effluent

Ramesh. F¹ and K. Nagarajan²

¹Department of Biological Sciences, University of Eastern Africa, Baraton P.O. Box 2500, Eldoret-30100, Kenya

²Department of Zoology, Sri Vasavi College, Erode - 638 316, India

Corresponding author: Ramesh. F, Department of Biological Sciences, University of Eastern Africa, Baraton P.O. Box 2500, Eldoret-30100, Kenya

Abstract. The histopathological changes are observed in the muscle tissue of the fresh water fish *Clarias batrachus* exposed to different concentrations of untreated and treated sago effluent. The concentration chosen for untreated effluent and treated effluent were 50% and 100%. The histology of muscle tissue showed various degrees of deterioration when compared to control. The deterioration was very much reduced in the treated sago effluent when compared to the untreated sago effluent.

Key words: *Clarias batrachus*, Sago effluent, histopathology.

1. INTRODUCTION

A thorough knowledge of normal histology is essential for the understanding of the altered structure seen in the various conditions of disease. The off target movement of chemicals used in industry and agriculture are usually unavoidable, these chemicals get into natural water and may cause significant tissue damage in fish (Mckim *et al.*, 1970; Reichenbach-Klinke, 1972; Horavath and Stammer, 1979; Rojik *et al.*, 1983; Bennedeczky *et al.*, 1984).

Histopathological alterations can be used as indicators for the effects of various pollutants on organisms and are a reflection of the overall health of the entire population in the ecosystem. These histopathological biomarkers are closely

related to other biomarkers of stress since many pollutants have to undergo metabolic activation in order to be able to provoke cellular changes in the affected organism (Fatma, 2009).

Generally industrial wastes includes a wide variety of chemicals all of these chemicals of industrial waste are toxic to animals and may cause death or sub lethal pathology of liver, kidneys, reproductive system, respiratory system or nervous system in both invertebrate and vertebrate aquatic animals. Histology acts as an integrated parameter, providing a more complete evaluation of the organisms' health, effectively monitoring the effects of exposure to environmental pollutants (Teh *et al.*, 1997; Van Der Oost *et al.*, 2003). Fish are sensitive indicators of pollutants present in water. These pollutants cause various physical and physiological alterations in fishes (Trivedi *et al.*, 2002).

The present investigation was an attempt to evaluate the potential toxic effects of sago effluent to the fish *Clarias batrachus*.

2. MATERIALS AND METHODS

Fingerlings of healthy *Clarias batrachus* procured from Bangalore and were brought to the laboratory and acclimatized for 15 days. The fish were well fed during the acclimatized period. Feeding was stopped one day before commencement of the experiment. The test individuals were killed by narcotization method. Muscle tissues were cut from the fishes and the histological studies were done using standard microtechniques.

3. RESULTS

Control

Muscle is the tissue of motion and is widely distributed in various organs of the body. It is composed of elongated muscle fibers, each an individual muscle cell, held together by connective tissues. The body musculature is relatively simple in

fishes. The fins are usually provided with individual small muscles, but the most complex organization is in the head region. Many individual muscles show an arrangement of fibers into bundles separated from each other by connective tissue portions. The nerves generally penetrate a muscle on its side and branch out as they penetrate the connective tissue.

Segmentation or metamerism of vertebrate musculature is seen clearly in the lateral muscles of the fishes. They are divided into myotomes or muscle segments, each of which is bent into a single V with the angle directed anteriorly. The function of these lateral muscles in almost all types of fishes is locomotion by swimming. Basically, alternate contractions passing posteriorly along the muscles on the two sides of the body result in the well known undulating movements of trunk and tail.

Each myotome is divided into an upper (epaxial) and a lower (hypaxial) half by a groove running along the side of the fish. Successive myotomes are separated by obliquely oriented connective tissue partitions (myosepta). The epaxial portion is separated from the hypaxial myotome by a fibrous septum running antero-posteriorly, parallel to the longitudinal axis. Removal of the skin reveals the zigzag arrangement of the myotomes with the myosepta.

An individual striated muscle fiber may be from 1 to 40 mm long and to 10-100mm in diameter. This large cell is multinucleated. The fibres are unbranched. Each fibre is enclosed in a thin membrane, the sarcolemma which is a specialized cell membrane. The protoplasm of the fibre, sarcoplasm contains five longitudinal myofibrils which extend throughout. Each myofibril is composed of two types of short myofilaments which are precisely arranged giving the appearance of transverse banding, the striations (**Fig.1**).

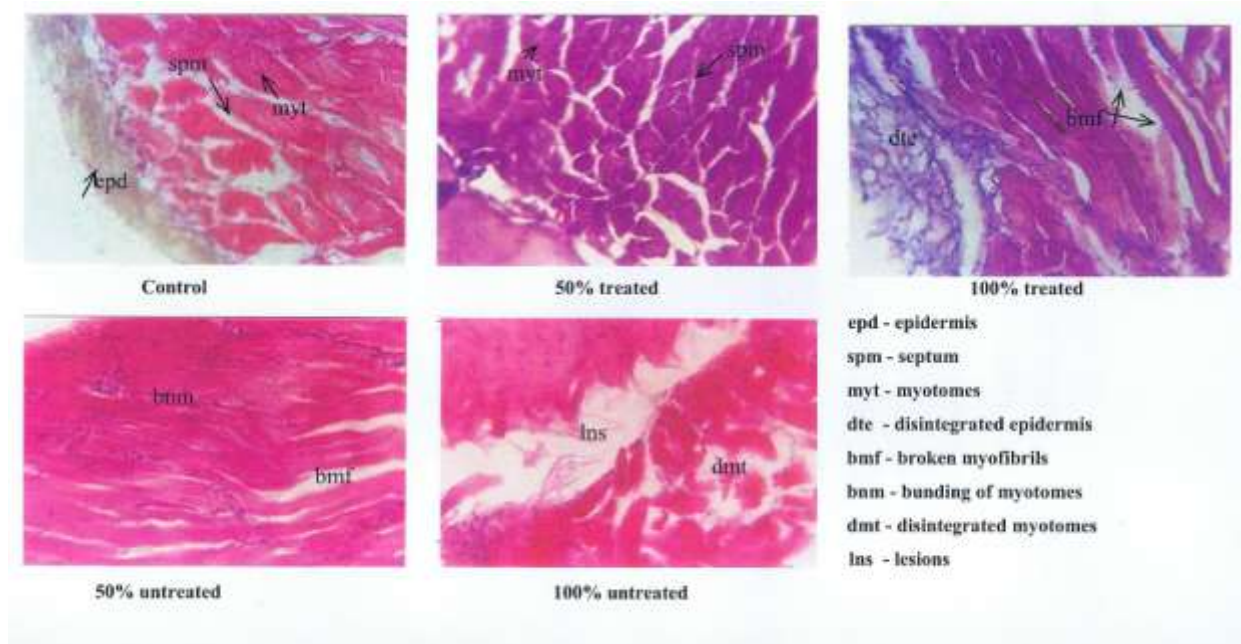


Figure.1. Histology of muscle tissue of *Clarias batrachus* exposed to 50%, 100% treated sago effluent and 50%, 100% untreated sago effluent.

50% Treated Sago Effluent

Histology of this group shows normal structure. Myotomes and myoseptum are seen clearly. Individual myotomes are separated by myoseptum, this forms the origin and insertion for muscle fibres from adjacent myotomes. The epidermis is not seen clearly.

100% Treated Sago Effluent

In the 100% treated effluent exposed fish, the impact is not very well pronounced. However in some places broken myofibrils are seen. The muscle seems to have lost the myoseptum that separates each myotome. Disintegrated epidermis is also seen in the section of muscle.

50% Untreated Sago Effluent

The individuals exposed to 50% untreated effluent shows markable changes in the section. Myofibrils are broken in many places. Myotomal septum is not distinct. Bundling of myotomes are also seen.

100% Untreated Sago Effluent

The individuals exposed to 100% concentration of untreated sago effluent shows disintegration of myotomes in several places. Bundling of myotomes is seen in few places and septum is not distinct. Lesions are observed in many places. Broken myofibrils are also observed.

4. DISCUSSION

In the present study the histopathology of muscle show progressive damage in the structure of muscle with increasing concentrations of the sago effluent. Similar observations have been made by Nagarajan and Suresh (2005) in the muscle tissue of the fish *Cirrhinus mrigala* with increasing concentrations of sago effluent. Sakr and Gabr, 1991; Abo and Amer, 1995 and Das and Mukherjee, (2000) have studied the effect of different pollutants on fish muscles.

Singh and Mehrotra (1999) have observed the damaged muscle layers in the fish *Nandus nandus* exposed to carbaryl. Anshu *et al.*, (1995) have studied the sublethal effect of quinolphos and padan on the muscle tissues of common carp *Cyprinus carpio*. Glycogen content was found to be depleted in the tissues as concentrations of toxicants increased.

Ayoola Simeon (2011) has observed mild lesion, necrosis, and inclusion of bodies, inflammation and cellular degeneration in the muscle tissue of the fish *O.niloticus* exposed to aqueous and ethanolic extracts of *Ipomoees aquatica* leaf. Bharat *et al.*, (2011) studied the histopathology of fish *Cyprinus carpio* exposed to sublethal concentrations of lead and cadmium. The fish showed marked thickening

and separation of muscle bundles with severe intracellular edema. Similar observation has been made by Das and Mukharjie (2000).

Elnemaki and Abuzinadah (2003) have observed focal areas of myolysis in the muscles of *O.spilurus* exposed to conta/insect 500/50 E.C. Abbas and Ali (2007) have noted the destruction and vacuolation of the muscle cells in *Oreochromis spp* exposed to chromium. Fatma (2009) observed the degeneration of muscle bundles with aggregation of inflammatory cells between them and focal areas of necrosis. Also, vacuolar degeneration in muscle bundles and atrophy of muscle bundles in fish exposed to different pollutants.

5. CONCLUSION

The above findings and the results of the present study indicate that the muscle is a sensitive tissue gets affected easily by the pollutants. The muscle tissue treated with untreated effluent exhibited marked histopathological changes when compared to treated effluent. The severity increased with higher concentrations of effluent. So the untreated effluent has more effect on fish *Clarias batrachus* than the treated effluent.

References

- [1] Abbas, H. and Ali, F. (2007) Study the effect of hexavalent chromium on some biochemical, cytological and histopathological aspects of *Oreochromis spp* fish. Pak. J. Biol. Sci. 10: 3973-3982.
- [2] Abu Nour, A. and Amer (1995) Impairment of muscle performance in the Nile catfish *Clarias lazera* in response to hostathion insecticide contamination and/or gamma irradiations. *J. Egypt. Gev. Soc. Zool.* 18: 153-175.
- [3] AnshuAmali, A., Elizabeth Jayanthi, F.X. and Cyril Arunkumar, L. (1995) Sublethal effect of quinolphos and padan on tissues glycogen of common carp. *Cyprinus carpio* (Tinn). *Polln Res.* 14 (3):295-298.
- [4] Ayoola Simeon (2011) Histopathology of Nile Tilapia (*Oreochromis niloticus*) juveniles exposed to aqueous and ethanolic extracts of *Ipomoea aquatica* leaf. *Int. J. Fish & Aquat.* Vol. 3(14): 244-257.
- [5] Benedeczky, I., Biro, P. and Schaff, Z. (1984) The effect of 2,4-D-containing herbicide (Diconirt) on the ultrastructure of carp, *Cyprinus carpio*, liver cells. *Acta. Biol. Szeged.* 30 : 107-125.

- [6] Bharat Bhuan Patnaik, HongrayHowrelia, J., Theresia Mathews and Selvanayagam. (2011) Histopathology of gill, liver, muscle and brain of *Cyprinus carpio communis* L. exposed to sublethal concentrations of lead and cadmium. *Afr. J. Biotech.* Vol 10(57): 12218-12223.
- [7] Das, B. and Mukherjee, S. (2000) A histopathological study of carp (*Labeo rohita*) exposed to hexachlorocyclohexane. *Vet. Arhiv.* 70(4): 169-180.
- [8] Elnemaki, F. and Abuzinadah, O. (2003) Effect of contra/insect 500/50 E.C. on the histopathology of *Oreochromis spilurus* fish. *Egypt. J. Aquat. Res. Fish.* 29:221-253.
- [9] Fatma, A.S. Mohamed (2009) Histopathological studies on *Tilapia zillii* and *Solea vulgaris* from Lake Qarum, Egypt. *World J. Fish. Mari. Sci.* 1(1): 29-39.
- [10] Horvath,I.and Stammer, A. (1979). Electron microscopical structure of gill lamellae of the *Leucisusidus* with patricular regard to the chloride cells and H₂S pollution. *Acta. Biol. Szeged.* 25 : 133-142
- [11] McKim, J.M., Christensen, G.M. and Hunt, E.P. (1970) Changes in the blood of brook trout, *Salvelinus fontinalis*, after short-term and long-term exposure to copper. *J. Fish. Res. Bd. Can.* 27 : 1883-1889.
- [12] Nagarajan, K. and Suresh, K. (2005) Observations on the changes in eye and muscle tissues of *Cirrhinus mrigala* exposed to sublethal concentrations of treated effluent. *J. Indus.Polln. Cont.* 21(1): 109-114.
- [13] ReichenabchKlinke,H.H.(1972)HistologisceandEnzymatischeVeranderungennachSchadstoffeinwirkungbeim Fish. *Verof. Inst. Kust-u. binnenfish.* 53 : 113-120.
- [14] Rojik, I.,Nemcsok, J. and Borass, L. (1983) Morphological and biochemical studies on liver, kidney and gill of fishes affected by pesticides. *Acta. Biol. Hung.* 34(1): 81-92.
- [15] Sakr, S. and Gabr (1991) Ultra structural changes induced by diazinon and neopybuthrin in skeletal muscles of *Tilapia nilotica*. *Proceed. Zool. Soc. A.R.E.* 21: 1-14.
- [16] Singh Sudha and Mehrotra Asha (1999) Histopathological changes induced by carbaryl in the intestine of fresh water fish *Nandus nandus*. *J Ecotoxico Environ Monit*, 11(2): 129-132.
- [17] Teh, S.J., Adams, S.M. and Hinton, D.E. (1997) Histopathological biomarkers in feral fresh water fish population exposed to different types of contaminant stress. *Aquat. Toxicol.* 37, 51-70.
- [18] Trivedi, S.P., Kumar, M., Misra, A., Banerjee, I and Soni, A. (2002) Impact of linear alkyl benezenesulohonate (LAS) on phosphatase activity in testis of the teleostean fish. *J. Environ. Biol.* 22(4):263-6.
- [19] Van Der Oost, R., Beyer, J. and Vermeuten, N.P.E. (2003) Fish bioaccumulation and biomarkers in environmental risk assasment: A review. *Environ. Toxicol. Pharmacol.* 13, 57-149.